



EN BLOC VERTEBRECTOMY FOR THORACOLUMBAR SPINE TUMORS: PRINCIPLES, TECHNIQUES, AND ILLUSTRATIVE CASES

VERTEBRECTOMIA EM BLOCO DE TUMORES DA COLUNA TORACOLUMBAR: PRINCÍPIOS, TÉCNICAS E CASOS ILUSTRATIVOS

VERTEBRECTOMÍA EN BLOQUE DE TUMORES DE LA COLUMNA TORACOLUMBAR: PRINCIPIOS, TÉCNICAS Y CASOS ILUSTRATIVOS

MATHEUS DA SILVA RIBEIRO¹ , VICTOR QUEIROZ GIACOMINI² , LUNA JEANNIE ALVES MANGUEIRA¹ , PEDRO FELISBINO JÚNIOR¹ , LUCAS LODOMIRO ARAUJO MELO¹ ,
RAFAEL DE SOUSA ELIAS¹ , PAULO HENRIQUE MARTINS SILVA¹ , SINVAL DORNELES FILHO¹ , GABRIEL JOÃO FRANCISCO DE SOUZA¹ , FERNANDO BALSIMELLI¹ ,
MURILO TAVARES DAHER¹ 

1. Centro de Reabilitação e Readaptação Dr. Henrique Santillo, Spine Group CRER, Goiânia, GO, Brazil.
2. Secretaria de Saúde do Distrito Federal (SES-DF), Distrito Federal, DF, Brazil.

ABSTRACT

En bloc vertebrectomy (EV) is an oncologic surgical technique aimed at the complete resection of vertebrae affected by tumors, in a single specimen and with negative margins, according to the principles proposed by Enneking. It is especially indicated for primary malignant tumors and aggressive benign tumors. Achieving adequate oncologic margins depends on careful preoperative planning, mainly based on the Weinstein-Boriani-Biagini (WBB) and Tomita classifications, which guide tumor extension, surgical approach, and technical strategy. This article systematically presents the oncologic principles of EV, clinical indications, surgical planning, and available technical approaches. The posterior-only approach is highlighted for its lower morbidity and effectiveness in selected cases, particularly in the thoracic and upper lumbar spine. Two illustrative cases demonstrate the practical application of the technique and reinforce the feasibility of the posterior-only approach. Despite its high morbidity, when properly indicated and planned, EV remains a potentially curative and effective strategy for the treatment of thoracolumbar spine tumors. **Level of Evidence III; Review Article.**

Keywords: Spinal Neoplasms; Surgical Oncology; Spine.

RESUMO

A *vertebrectomia em bloco* (VB) é uma técnica cirúrgica oncológica que visa a ressecção completa de vértebras acometidas por tumores, em peça única e com margens livres, conforme os princípios propostos por Enneking. É especialmente indicada para tumores primários malignos e tumores benignos agressivos. A obtenção de margens oncológicas adequadas depende de criterioso planejamento pré-operatório, baseado principalmente nas classificações de Weinstein-Boriani-Biagini (WBB) e Tomita, que orientam a extensão tumoral, via de acesso e técnica cirúrgica. Este artigo apresenta de forma sistematizada os fundamentos oncológicos da VB, as indicações clínicas, o planejamento cirúrgico e as abordagens técnicas disponíveis. A técnica por via posterior isolada é destacada por sua menor morbidade e eficácia em casos selecionados, especialmente na coluna torácica e lombar alta. Dois casos ilustrativos demonstram a aplicação prática da técnica e reforçam a viabilidade da abordagem posterior isolada. Apesar de sua elevada morbidade, quando indicada e planejada criteriosamente, a VB permanece como estratégia potencialmente curativa e eficaz no tratamento dos tumores da coluna toracolumbar. **Nível de Evidência III; Artigo de Revisão.**

Descritores: Neoplasias da Coluna Vertebral; Oncologia Cirúrgica; Coluna Vertebral.

RESUMEN

La *vertebrectomía en bloque* (VB) es una técnica quirúrgica oncológica que tiene como objetivo la resección completa de las vértebras afectadas por tumores, en una sola pieza y con márgenes libres, conforme a los principios propuestos por Enneking. Está especialmente indicada para tumores primarios malignos y tumores benignos agresivos. La obtención de márgenes oncológicos adecuados depende de una planificación preoperatoria minuciosa, basada principalmente en las clasificaciones de Weinstein-Boriani-Biagini (WBB) y Tomita, que orientan sobre la extensión tumoral, la vía de acceso y la estrategia quirúrgica. Este artículo presenta de forma sistematizada los fundamentos oncológicos de la VB, las indicaciones clínicas, la planificación quirúrgica y las diferentes técnicas disponibles. Se destaca el abordaje posterior exclusivo por su menor morbilidad y eficacia en casos seleccionados, especialmente en la columna torácica y lumbar alta. Dos casos ilustrativos demuestran la aplicación práctica de la técnica y refuerzan la viabilidad del abordaje posterior exclusivo. A pesar de su elevada morbilidad, cuando está indicada y se planifica cuidadosamente, la VB sigue siendo una estrategia potencialmente curativa y eficaz en el tratamiento de los tumores de la columna toracolumbar. **Nivel de Evidencia III; Artículo de Revisión.**

Descriptor: Neoplasias de la Columna Vertebral; Oncología Quirúrgica; Columna Vertebral.

Study conducted by the Centro de Reabilitação e Readaptação Dr. Henrique Santillo, Spine Group (CRER), Av. Ver. José Monteiro, 1655, Setor Negrão de Lima, Goiânia, GO, Brazil. 74653-230.
Correspondence: Murilo Tavares Daher. Rua Sistina, quadra 03, lote 18, Goiânia, GO, Brazil. 74866-012. drmurilodaher@gmail.com.br



INTRODUCTION

Vertebrectomy *en bloc* (VB) is a surgical technique in which one or more vertebrae are resected in a single piece, without macroscopic violation of the tumor. Initially described by Tomita et al. in the treatment of spinal tumors, its main objective is to obtain neoplasm-free surgical margins, according to the principles of oncological surgery proposed by Enneking.¹⁻⁴ Unlike intralesional resections, which fragment the tumor and increase the risk of contamination and local recurrence, VB allows greater oncological control by preserving the integrity of the tumor specimen.^{2,5,6} Its classic indications include primary malignant tumors of the spine, such as chordomas, chondrosarcomas, and sarcomas, as well as aggressive benign tumors, such as giant cell tumors. Although historically used in the treatment of solitary vertebral metastases, advances in stereotactic radiosurgery have reduced this application, offering effective local control and comparable survival with lower morbidity in selected cases.^{7,8}

Historical evolution of the technique

Lièvre and Stener were the first to describe vertebral resection in the treatment of spinal tumors.^{9,10} Subsequently, Roy-Camille popularized the technique by introducing technical improvements with pedicle instrumentation after extensive oncological resections.¹¹ In 1997, Tomita et al.⁵ raised the technical standard by describing total *en bloc* vertebrectomy, standardizing the technique for resection of primary vertebral tumors. The Tomita Method consists of sequential resection of the affected vertebra: removal of the posterior elements at the level of the pedicles, removal of the vertebral body in a single piece, and reconstruction of the anterior spine. In 2009, Kawahara et al. refined this technique, consolidating principles such as bilateral pedicle osteotomy and proper management of adjacent neural and vascular structures.¹²

Spinal Oncology Surgery Fundamentals

The classification proposed by Enneking, which categorizes surgical margins as intralesional, marginal, wide, and radical, remains a fundamental conceptual reference. However, applying these principles to spinal surgery requires specific adaptations due to the complex regional anatomy and close relationship with critical neurovascular and visceral structures.⁴

- **Intralesional resection:** occurs when the surgical plane passes through the tumor, with partial removal of the lesion and persistence of residual neoplasia. Often used in decompression or curettage procedures, it is mainly aimed at symptomatic relief and neurological decompression. Due to the disruption of the tumor capsule, it is associated with high rates of local recurrence.⁷

- **Marginal resection:** consists of removing the tumor in a single piece, along with the reactive pseudocapsule, but with a risk of microscopic peripheral involvement. In spinal surgery, this is often the most viable oncological margin due to its proximity to critical structures such as the dura mater, nerve roots, and large vessels.^{2,13,14}

- **Wide resection:** consists of removing the tumor with a margin of healthy tissue, ensuring that there is no microscopic invasion at the surgical edges. Although it represents the gold standard from an oncological point of view, its application in the thoracolumbar spine is limited by the proximity of neural, vascular, and visceral structures. However, in cases of intracompartmental tumors restricted to the vertebral body, obtaining wide margins may be feasible.^{6,15}

- **Radical resection:** consists of excising the entire anatomical compartment containing the tumor. In the column, the application of this concept is restricted, since its implementation would involve the removal of vital structures. Radical resections are generally limited to the sacrococcygeal region, as in the treatment of chordomas, where total resection of the sacrum may be considered.^{16,17}

Eninking Adequate (EA) resection is defined as resection that respects the tumor boundaries, with wide or marginal margins, while Eninking Inadequate (EI) resection is defined as resection that violates the tumor capsule, resulting in intralesional margins and compromised local control of the disease. A central principle in spinal

oncology is that the first surgery represents the best chance for a cure. Unlike long bones, where recurrence can be managed with extensive resection or amputation, recurrence in the spine infiltrates scar tissue and critical neurovascular structures, making a second resection with adequate margins difficult. Therefore, whenever indicated, VB should be considered as the initial approach.^{6,15,16,18}

Indications

In the thoracolumbar spine, VB may be indicated in: (1) aggressive benign primary tumors, (2) primary malignant tumors, and (3) isolated spinal metastases with controlled systemic disease—the latter indication being controversial, given the evolution of stereotactic radiosurgery.^{7,8}

The primary tumors most frequently treated with this technique are: chordoma, chondrosarcoma, osteosarcoma, giant cell tumor, solitary plasmacytoma, Ewing sarcoma, and osteoblastoma. Lesions previously treated with conventional approaches, such as decompressive laminectomies, in the presence of recurrence, may also be candidates for *en bloc* resection.^{5,19,20}

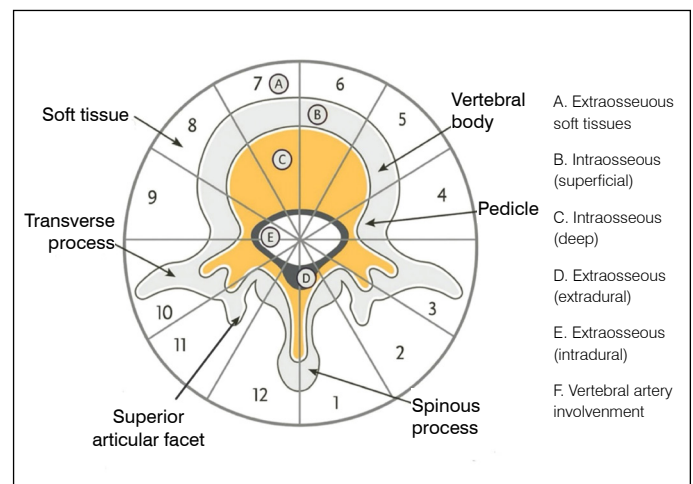
Preoperative Planning

The success of VB depends on adequate preoperative planning, guided by imaging tests and cancer staging for the best strategy. The main tool in this process is the *Weinstein–Boriani–Biagini (WBB)* classification.^{16,21}

The WBB system (Figure 1) divides the vertebra into 12 radial zones and 5 concentric layers (A to E), allowing the extent of the tumor to be described. This system directly guides the choice of access route and osteotomies necessary to achieve safe oncological margins. Lesions restricted to the vertebral body or pedicles, for example, can be resected exclusively via the posterior approach. Tumors with significant anterior extension and involvement of large vessels may require combined approaches.²¹

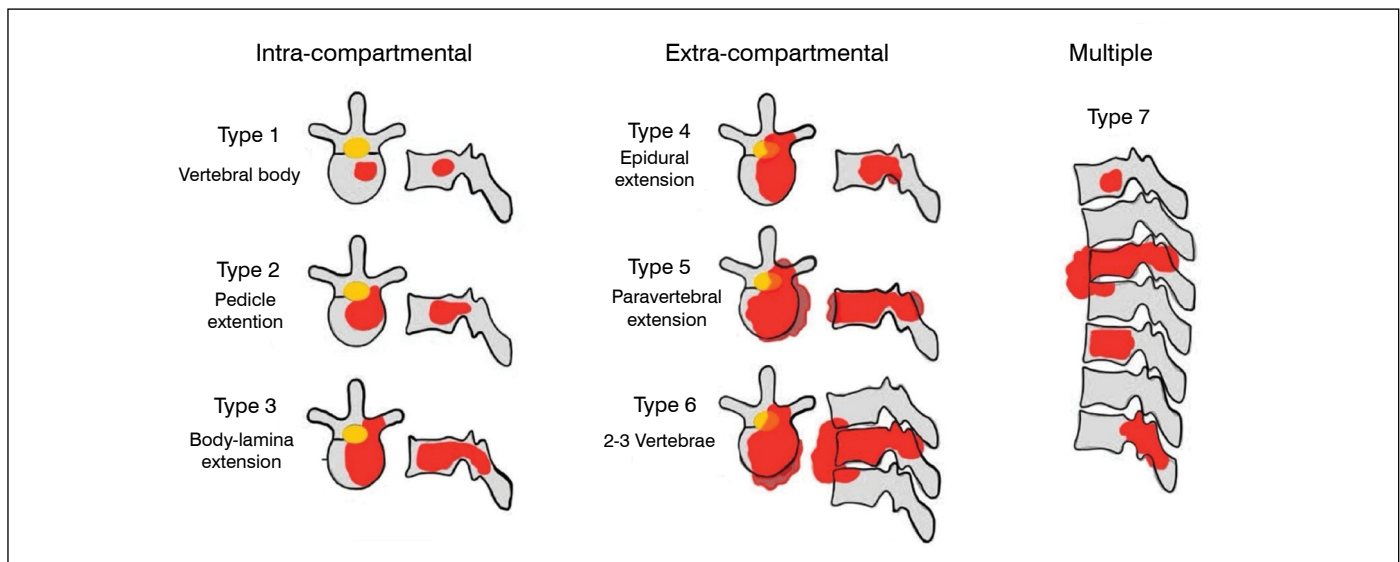
Planning osteotomies is a fundamental part of the surgical strategy. To enable removal of the vertebra in a single piece, the vertebral arch must be sectioned at two points, ensuring mobilization of the bone segment without spinal cord injury. For *en bloc* removal of the posterior complex, bilateral pedicle osteotomy or combined osteotomy of one pedicle and the contralateral lamina may be performed. The choice depends on the pattern of tumor involvement mapped by WBB.^{15,18,22}

In addition to WBB, cancer staging is another pillar of planning. Enneking's classification, originally proposed for musculoskeletal tumors, was modified by Tomita et al.¹⁵ for application to vertebral tumors. Tomita's classification (Figure 2) provides a basis for determining whether the goal will be an intralesional, marginal, or wide margin, with the aim of reducing the likelihood of recurrence.^{13,23}



Adapted from: Boriani S, et al.²¹

Figure 1. Weinstein–Boriani–Biagini (WBB) classification.



Adapted from: Tomita K, et al.¹⁵

Figure 2. Tomita classification.

Decision on access route

The choice of surgical approach for VB should take into account the tumor location, oncological margins, and relationship with neurovascular structures. The WBB classification provides the anatomical basis for this decision.²⁴

- Previous isolated approach: indicated for small tumors restricted to the vertebral body (layers A and B, sectors 8 to 5), located in the thoracic or lumbar spine, without posterior invasion (layer C or D).
- Isolated posterior approach: tumors of the posterior elements, vertebral body, or eccentric growth, especially in the thoracic and upper lumbar spine. Adequate margins require no pedicle involvement (sectors 4 or 9 free). Involvement of layers D (epidural) and/or A (adjacent soft tissues) results in intralesional margins during dissection of the dura mater and anterior structures.
- Anterior approach followed by posterior: thoracic or lumbar lesions with anterior growth (layer A) in which an anterior approach can be performed to obtain a wide or marginal margin with direct visualization.
- Posterior approach followed by combined anteroposterior approach: indicated for large tumors of the lumbar spine with significant anterior extension. Despite its technical complexity and association with higher morbidity, this strategy avoids the need to sacrifice unaffected roots and allows for safer removal in complex cases.
- Triple approach for L5 tumors: applied to tumors located in L5, requiring three surgical procedures: (1) contralateral approach to the tumor for safe release of the aortic/caval bifurcation, (2) posterior access, and (3) simultaneous anterior and posterior approach, with the patient in the lateral decubitus position, allowing three-dimensional control of the lesion and adjacent structures.

Surgical technique

Isolated posterior approach

VB via the posterior approach alone is effective in selected cases, especially in the thoracic and upper lumbar spine, provided there is no significant invasion of the anterior structures or direct involvement of the great vessels (types 1 to 4 and some cases of types 5 and 6 according to Tomita). In this topography, the anatomical arrangement allows safe mobilization of the ventral structures, enabling complete resection through a single access. This approach allows for adequate oncological margins with lower morbidity, avoiding the additional risks associated with combined approaches.^{12,15,16,25,26}

Surgical exposure and instrumentation

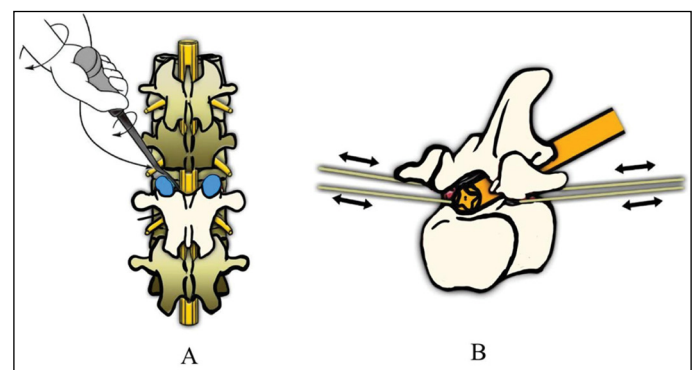
The patient is positioned in the prone position on a radiolucent surgical table, supported at four points. A wide longitudinal posterior

incision is made, usually involving two to three levels above and below the affected segment. After subperiosteal dissection of the paravertebral musculature, the posterior elements are exposed up to the transverse processes. Next, pedicle screws are inserted into the upper and lower levels, according to the number of vertebrae to be resected. In multiple resections of two or more vertebrae or in patients with low bone stock, it is mandatory to extend this fixation to three or more levels.^{15,16,26}

Block laminectomy and posterior osteotomies

After initial instrumentation, *en bloc* resection of the posterior elements of the affected vertebra is performed, including the laminae, spinous processes, facets, and pedicles. This step provides safe access to the spinal cord and enables subsequent removal of the vertebral body with oncological margins. Initially, a laminectomy is performed on the adjacent levels, down to the lower portion of the upper pedicle and upper portion of the lower pedicle. Next, the yellow ligament is sectioned superiorly and inferiorly, and the posterior surface of the dural sac is released. Subsequently, osteotomy of the pedicles is performed with the aid of a wire saw (T-saw). The T-saw guide is introduced through the foramen in the craniocaudal direction, surrounding the pedicle in a plane dorsal to the nerve root (Figure 3). The saw is then connected to the guide and positioned around the pedicles, which are sectioned with controlled reciprocal movements. This step can also be performed using curved chisels or ultrasonic osteotomes.^{15,25}

After bilateral pedicle sectioning, the posterior arch is removed



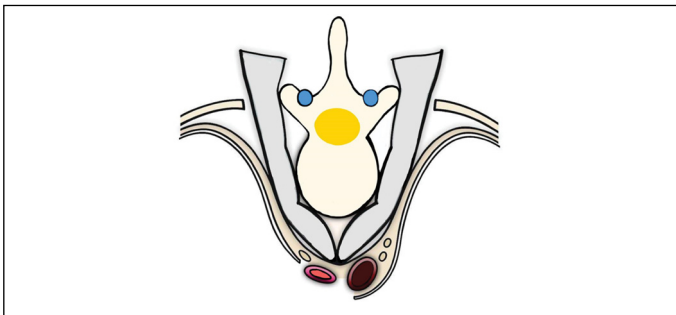
Adapted from: Tomita K, et al.¹⁵

Figure 3. (A) Introduction to the T-saw guide. (B) Pedicure using the T-saw.

en bloc. With the dura mater exposed, it can be dissected and protected for the next steps. The nerve roots at the tumor level are identified and sectioned as necessary to obtain adequate margins. In the thoracic spine, it is possible to sacrifice the segmental root without significant functional impairment; in the lumbar spine, however, the roots should be preserved to maintain motor and sensory function.²⁶ Finally, it is recommended to apply bone wax to the cut surfaces of the pedicles to reduce bleeding and minimize the spread of tumor cells.

Anterior dissection and release of the vertebral body

With the spinal cord protected, the release of the structures surrounding the vertebral body begins. The blunt dissection, performed with curved spatulas and fingers, should respect the tumor margins and explore the plane between the vertebral body and elements such as the pleura, aorta, or psoas/iliac muscles. In the thoracic spine, the intercostal vessels are identified, ligated, and sectioned, the pleurae are carefully retracted, and bilateral sectioning of the corresponding nerve roots is preferred to prevent avulsion injuries. When the surgeon's fingertips meet on the anterior surface of the vertebral body (Figure 4), spatulas or malleable valves of increasing size are progressively inserted to expand the dissection area. A pair of the largest retractors is then held in place, protecting adjacent tissues and organs and enlarging the surgical field for manipulation of the anterior spine.



Adapted from: Tomita K, et al.¹⁵

Figure 4. Dissection with fingers.

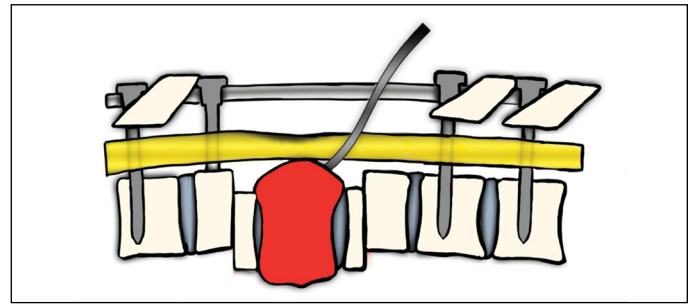
Temporary unilateral stabilization

Before vertebral osteotomy, temporary stabilization^{12,26} is performed by fixing a rod on one side to prevent instability during manipulation and subsequent bone sectioning. To enable work on both sides of the lesion, the side of the stem can be switched for temporary stabilization.

Osteotomy of the vertebral body and removal of the piece

With the vertebra previously isolated from its posterior elements and the anterior dissection completed, osteotomy of the vertebral body or discectomy is performed, superiorly and inferiorly, enabling its removal in a single piece. The cut levels are confirmed by fluoroscopy, and release can be performed with osteotomes, cold scalpels, and wire saws (Gigli or T-saw). In the wire saw technique, a flexible guide is inserted through the adjacent neural foramina, bypassing the vertebral body anteriorly. The wire is pulled from the outside in, promoting horizontal and continuous bone cutting. Tomita et al.^{15,27} demonstrated that T-saw presents a lower risk of tumor spread than Gigli saw.

After complete release of bone, soft tissue, and adhesions from the dural sac, the vertebra is carefully mobilized and removed posteriorly (Figure 5). Before starting this step, you can gently distract the screws, tensioning the tissues to be released and increasing the working space for removal of the vertebral body. A controlled rotation maneuver is performed around the spinal cord, taking care to avoid traction or compression. Lu et al.²⁶ described the "reverse rotation" technique, in which the part is initially rotated toward the affected side to expose the dorsal structures. Next, controlled opposite rotation (up to 180°) is performed, allowing



Adapted from: Tomita K, et al.¹⁵

Figure 5. Release of adhesions between tumor pseudocapsule and dural sac with dissector, after osteotomy of vertebral bodies.

direct dissection of the anterior structures via the posterior route without damaging the tumor capsule. Unlike the single, progressive rotation described by Tomita, reverse rotation involves sequential bidirectional mobilization, allowing for greater oncological safety in tumors with ventral involvement.

Previous reconstruction and final instrumentation

Reconstruction of the anterior column is performed with structural grafts or cages. The graft is positioned between the remaining vertebral bodies, and posterior instrumentation is completed with controlled compression. In the lumbar spine, expandable cages can facilitate insertion, minimizing manipulation of the roots. Bilateral rods, crosslinks, and spacers are used to restore three-dimensional stability. Three or four rods can be used to increase local stability. Finally, hemostatic control and radiographic confirmation of implant positioning are performed.

Anteroposterior Combined Approach

It consists of two sequential stages: an anterior (or lateral) phase for release and resection of the affected vertebral body, followed by a posterior phase to complete neural decompression and definitive stabilization of the spine. According to Kawahara et al.,¹² this strategy is useful in Tomita type 5 or 6 tumors, with significant invasion of the anterior portion of the vertebra or located in the lower lumbar region (L3–L5), where isolated posterior access does not provide safe visualization of adjacent vascular and visceral structures.^{12,15,28}

- **Previous phase.** Position the patient in the supine or lateral position, depending on the location of the injury. Thoracotomy or thoracoscopy is used for thoracic tumors, thoracoabdominal access for thoracolumbar lesions (T11–L2), and a retroperitoneal approach for lumbar tumors (L3–L5). This step allows direct dissection of the aorta, vena cava, and soft tissues with tumor invasion. Corpectomy is performed after ligating the segmental vessels, releasing the upper and lower intervertebral discs, and resecting compromised adjacent structures. Often, an anterior cage is already positioned for spinal reconstruction.^{12,28}
- **Later stage.** With the patient repositioned in the prone position, laminectomy and inspection of the spinal canal are performed, which is already partially decompressed by the previous removal of the vertebral body. The final posterior instrumentation is then performed with pedicle screws and rods, completing the arthrodesis and closure by planes.^{12,29}

The anteroposterior approach offers better vascular control, direct visualization of visceral structures, and greater safety in tumors with anterior invasion, in addition to allowing immediate anterior reconstruction. However, it is more invasive, with longer operating times, bleeding, and morbidity, and may require two surgical procedures. Its use should be reserved for cases in which the posterior route alone does not guarantee safe margins or adequate neurovascular protection.^{28–30}

Posteroanterior Combined Approach

The combined posteroanterior approach applies the principles of 360° resection, but reverses the classic sequence, starting with the posterior approach and continuing with the anterior approach. This

strategy allows early neural decompression and initial stabilization of the spine, which is particularly advantageous in cases with critical spinal cord compression and instability.^{18,31}

Two-step technique: posterior–anterior

With the patient initially in the prone position, the posterior elements are exposed and pedicle instrumentation is placed at levels adjacent to the affected vertebra. When necessary, laminectomy is performed to decompress the spinal cord and osteotomy of the pedicles. Posterior instrumentation provides stability during subsequent manipulation, especially during anterior removal of the vertebral body.^{18,31,32}

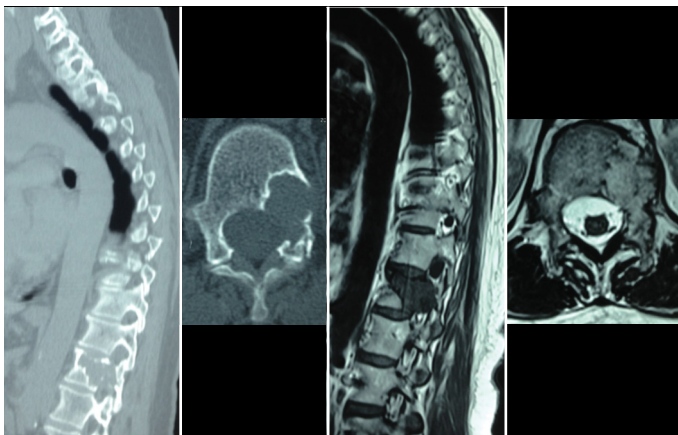
In the second stage, with the patient repositioned in the supine or lateral decubitus position, the anterior approach is performed, defined according to the topography of the lesion (thoracotomy, thoracoabdominal, or retroperitoneal). Careful dissection of the visceral and vascular structures allows access to the vertebral body for *en bloc* resection. Reconstruction of the anterior column is performed with expandable cages or structural grafts, which may be supplemented with direct anterior fixation or maintained with the support of previously installed posterior instrumentation. (31–33) The availability of expandable cages that allow controlled distraction can prevent return to the posterior pathway (third stage) for compression of the cage between adjacent vertebrae.^{18,31–33}

Complications

Although it offers adequate local control in thoracolumbar tumors, *en bloc* vertebrectomy is associated with high morbidity, with complication rates reaching up to 50%. The most frequent complications are neurological deficit (57%), cerebrospinal fluid leak (19.6%), surgical site infection (14%), and failure of the synthetic material (14%). The main predictors of complications are advanced age, metastatic disease, adjuvant radiotherapy/chemotherapy, and intralesional margin. Resection at the L5 level, in particular, was associated with longer surgical time and greater blood loss.³⁴

Illustrative case 1

Female, 65 years old, history of resection of chondrosarcoma of the rib head at T12. It evolved with local recurrence and progressive back pain, without neurological deficit. The images showed a lytic lesion at T12 extending to the left pedicle and soft tissues (WBB 2–6, A–D; Tomita 5). A posterior *en bloc* vertebrectomy was performed with asymmetric osteotomy (right pedicle + left lamina), avoiding tumor violation. Discectomies at T11–T12 and T12–L1. Reconstruction with expandable cage and arthrodesis from T10 to L2. (Figures 6 and 7)

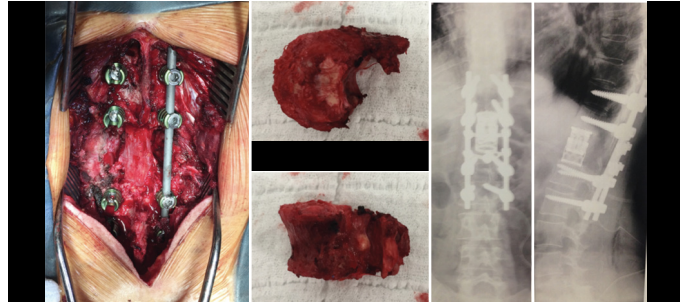


Source: Authors.

Figure 6. CT scan (left) of the thoracic spine showing an expansive lytic lesion at T12, with destruction of the vertebral body and involvement of the left pedicle, involvement of paravertebral soft tissues on the left, without invasion of large vessels or visceral structures. MRI (right) shows lobulated masses, involvement of the spinal canal, with no signs of spinal cord invasion.

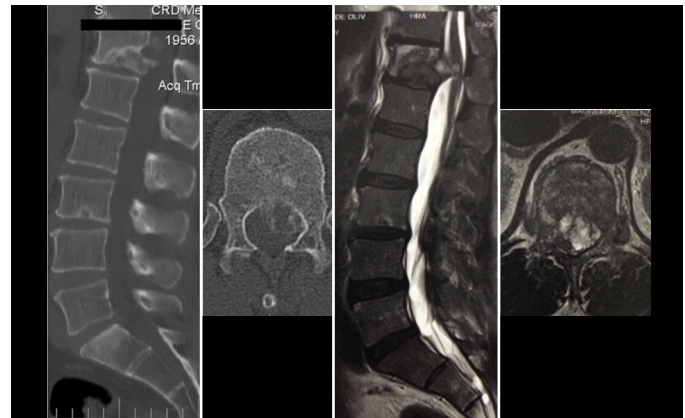
Illustrative case 2

Male, 59 years old, history of severe low back pain, no neurological deficit. MRI showed a lytic lesion at T12 with involvement of the canal and left pedicle (WBB 3–8, A–D; Tomita 5). The pathological examination confirmed the diagnosis of low-grade chondrosarcoma. Vertebrectomy performed on T12 block via isolated posterior approach with bilateral pedicle osteotomy and amputation of the T12 root on the left. Reconstruction with expandable cage and T10–L2 arthrodesis. (Figures 8 and 9)



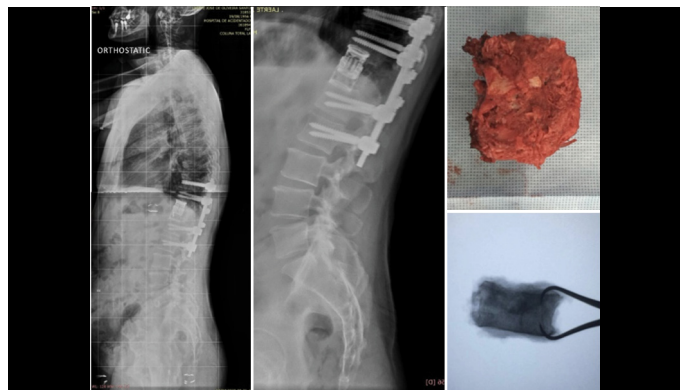
Source: Authors.

Figure 7. Intraoperative and radiographic images after T12 *en bloc* vertebrectomy, T10–L2 instrumentation, and anterior reconstruction with expandable cage.



Source: Authors.

Figure 8. CT scan (left) of the lumbar spine showing expansive lytic lesion at T12, compromising the left pedicle. There is extension to the paravertebral soft tissues on the left, without invasion of large vessels or visceral structures. MRI (right) shows lobulated mass, involvement of the spinal canal, and compression of neural structures, with no signs of intradural invasion.



Source: Authors.

Figure 9. Postoperative radiographs with posterior instrumentation of T10–L2 and anterior reconstruction with expandable cage, after *en bloc* vertebrectomy of T12. On the right, surgical specimen of T12 resected *en bloc*.

CONCLUSION

En bloc vertebrectomy is the technique of choice for malignant primary tumors and aggressive benign tumors of the thoracolumbar spine. When performed with oncological planning and appropriate selection of the access route, it allows satisfactory surgical margins and effective local control to be achieved. Despite the high morbidity

rate, this is a viable and potentially curative strategy, especially when performed as a first-line approach in centers specializing in spinal cancer surgery.

All authors declare no potential conflict of interest related to this article.

CONTRIBUTIONS OF THE AUTHORS: Each author contributed individually and significantly to the development of this article. RMS: project design and management, conceptualization, research, formal analysis, writing (original draft, revision, editing); GVQ: visualization, editing; MLJA: writing - revision and editing; JPF: conceptualization; MLLA: conceptualization, validation; ERS: writing - revision; MSPH: revision and editing; FSD: writing - revision; SGJF: writing - revision and editing; BF: writing - revision and editing; DMT: ideation, conceptualization, supervision, validation, writing - revision.

REFERENCES

- Tomita K, Toribatake Y, Kawahara N, Ohnari H, Kose H. Total en bloc spondylectomy and circumspinal decompression for solitary spinal metastasis. *Paraplegia*. 1994;32(1):36-46. doi: 10.1038/sc.1994.7.
- Amendola L, Cappuccio M, De Iure F, Bandiera S, Gasbarrini A, Boriani S. En bloc resections for primary spinal tumors in 20 years of experience: effectiveness and safety. *Spine J*. 2014;14(11):2608-17. doi: 10.1016/j.spinee.2014.02.030.
- Cloyd JM, Acosta FL Jr, Polley MY, Ames CP. En bloc resection for primary and metastatic tumors of the spine: a systematic review of the literature. *Neurosurgery*. 2010;67(2):435-44; discussion 444-5. doi: 10.1227/01.NEU.0000371987.85090.FF.
- Enneking WF. A system of staging musculoskeletal neoplasms. *Clin Orthop Relat Res*. 1986;(204):9-24.
- Tomita K, Kawahara N, Baba H, Tsuchiya H, Fujita T, Toribatake Y. Total en bloc spondylectomy. A new surgical technique for primary malignant vertebral tumors. *Spine*. 1997;22(3):324-33. doi: 10.1097/00007632-199702010-00018.
- Charest-Morin R, Fisher CG, Varga PP, Gokaslan ZL, Rhines LD, Reynolds JJ, et al. En Bloc Resection Versus Intraleisional Surgery in the Treatment of Giant Cell Tumor of the Spine. *Spine*. 2017;42(18):1383-1390. doi: 10.1097/BRS.0000000000002094.
- McVeigh LG, Linzey JR, Strong MJ, Duquette E, Evans JR, Szerlip NJ et al. Stereotactic body radiotherapy for treatment of spinal metastasis: A systematic review of the literature. *Neurooncol Adv*. 2024;6:iii28-iii47. doi: 10.1093/onoajnl/vdad175.
- Kite T, Jaffe S, Yadlapalli V, Verma R, Li J, Karlovits S, et al. A systematic review of stereotactic radiosurgery for metastatic spinal sarcomas. *J Neurooncol*. 2025;172(1):153-162. doi: 10.1007/s11060-024-04892-z.
- Lièvre JA, Darcy M, Pradat P, Camus JP, Bénichou C, Attali P, et al. Giant cell tumor of the lumbar spine: total spondylectomy in 2 states. *Rev Rhum Mal Osteoartic*. 1968 Mar;35(3):125-30.
- Stener B. Total spondylectomy in chondrosarcoma arising from the seventh thoracic vertebra. *J Bone Joint Surg Br*. 1971;53(2):288-95.
- Roy-Camille R, Saillant G, Mazel CH, Monpierre H. Total vertebrectomy as treatment of malignant tumors of the spine. *Chir Organi Mov*. 1990;75(1 Suppl):94-6.
- Kawahara N, Tomita K, Murakami H, Demura S. Total en bloc spondylectomy for spinal tumors: surgical techniques and related basic background. *Orthop Clin North Am*. 2009;40(1):47-63. vi. doi: 10.1016/j.oocl.2008.09.004.
- Chan P, Boriani S, Fourny DR, Biagini R, Dekutoski MB, Fehlings MG, et al. An assessment of the reliability of the Enneking and Weinstein-Boriani-Biagini classifications for staging of primary spinal tumors by the Spine Oncology Study Group. *Spine*. 2009;34(4):384-91. doi: 10.1097/BRS.0b013e3181971283.
- D'Amore T, Boyce B, Mesfin A. Chordoma of the mobile spine and sacrum: clinical management and prognosis. *J Spine Surg*. 2018;4(3):546-552. doi: 10.21037/jss.2018.07.09.
- Tomita K, Kawahara N, Murakami H, Demura S. Total en bloc spondylectomy for spinal tumors: improvement of the technique and its associated basic background. *J Orthop Sci*. 2006;11(1):3-12. doi: 10.1007/s00776-005-0964-y.
- Boriani S, Gasbarrini A, Bandiera S, Ghermandi R, Lador R. En Bloc Resections in the Spine: The Experience of 220 Patients During 25 Years. *World Neurosurg*. 2017;98:217-229. doi: 10.1016/j.wneu.2016.10.086.
- Fourny DR, Rhines LD, Hentschel SJ, Skibber JM, Wolinsky JP, Weber KL, et al. En bloc resection of primary sacral tumors: classification of surgical approaches and outcome. *J Neurosurg Spine*. 2005;3(2):111-22. doi: 10.3171/spi.2005.3.2.0111.
- Bohinski RJ, Rhines LD. Principles and techniques of en bloc vertebrectomy for bone tumors of the thoracolumbar spine: an overview. *Neurosurg Focus*. 2003;15(5):E7. doi: 10.3171/foc.2003.15.5.7.
- Boriani S, Biagini R, De Iure F, Bertoni F, Malaguti MC, Di Fiore Met al. En bloc resections of bone tumors of the thoracolumbar spine. A preliminary report on 29 patients. *Spine*. 1996;21(16):1927-31. doi: 10.1097/00007632-199608150-00020.
- Heary RF, Vaccaro AR, Benevenia J, Cotler JM. "En-bloc" vertebrectomy in the mobile lumbar spine. *Surg Neurol*. 1998;50(6):548-56. doi: 10.1016/s0090-3019(98)00078-0.
- Boriani S, Weinstein JN, Biagini R. Primary bone tumors of the spine. Terminology and surgical staging. *Spine (Phila Pa 1976)*. 1997;22(9):1036-44. doi: 10.1097/00007632-199705010-00020.
- Sciubba DM, De la Garza Ramos R, Goodwin CR, Xu R, Bydon A, Witham TF, et al. Total en bloc spondylectomy for locally aggressive and primary malignant tumors of the lumbar spine. *Eur Spine J*. 2016;25(12):4080-4087. doi: 10.1007/s00586-016-4641-y.
- K Singh, Colman M. *Surgical Spinal Oncology: Contemporary Multidisciplinary Strategies*. In: Nolte, MT, Colman, M. *Tumor Classification and Staging Systems in Orthopaedic Spine Surgery*. Nova York: Springer; 2020. p. 27-37.
- Boriani S. *En bloc* resection in the spine: a procedure of surgical oncology. *J Spine Surg*. 2018;4(3):668-676. doi: 10.21037/jss.2018.09.02.
- Louie PK, Khan JM, Miller I, Colman MW. All-posterior total *en bloc* spondylectomy for thoracic spinal tumors. *Ann Transl Med*. 2019;7(10):227. doi: 10.21037/atm.2019.04.89.
- Lu M, Hou C, Chen W, Lei Z, Dai S, Du Set al. En Bloc Resection of Thoracic and Upper Lumbar Spinal Tumors Using a Novel Rotation-Reversion Technique through Posterior-Only Approach. *Clin Orthop Surg*. 2025;17(2):346-353. doi: 10.4055/cios24377.
- Tomita K, Kawahara N. The threadwire saw: a new device for cutting bone. *J Bone Joint Surg Am*. 1996;78(12):1915-7.
- Araujo AO, Narazaki DK, Teixeira WGJ, Ghilardi CS, Araujo PHXN, Zerati AE, et al. En bloc vertebrectomy for the treatment of spinal lesions. Five years of experience in a single institution: a case series. *Clinics*. 2018;73:e95. doi: 10.6061/clinics/2018/e95.
- Dang L, Liu Z, Liu X, Jiang L, Yu M, Wu F, et al. Sagittal en bloc resection of primary tumors in the thoracic and lumbar spine: feasibility, safety and outcome. *Sci Rep*. 2020;10(1):9108. doi: 10.1038/s41598-020-65326-0.
- Tang Y, Li H, Liu S, Liu J, Zhou H, Liu X, et al. Perioperative complications of en bloc resection and anterior column reconstruction for thoracic and lumbar spinal tumors. *BMC Musculoskelet Disord*. 2024;25(1):364. doi: 10.1186/s12891-024-07408-y.
- Shah AA, Paulino Pereira NR, Pedlow FX, Wain JC, Yoon SS, Hornicek FJ, et al. Modified En Bloc Spondylectomy for Tumors of the Thoracic and Lumbar Spine: Surgical Technique and Outcomes. *J Bone Joint Surg Am*. 2017;99(17):1476-1484. doi: 10.2106/JBJS.17.00141.
- Luzzati A, Conti S, Sperduti I, Scotto Di Uccio A, Mazzoli S, et al. En-bloc spondylectomy in the lumbar spine: indications, results and complications in a series of 47 patients affected by primary malignant bone tumors. *Arch Orthop Trauma Surg*. 2024;144(5):2027-2038. doi: 10.1007/s00402-024-05274-w.
- Kawahara N, Tomita K, Murakami H, Demura S, Yoshioka K, Kato S. Total en bloc spondylectomy of the lower lumbar spine: a surgical techniques of combined posterior-anterior approach. *Spine*. 2011;36(1):74-82. doi: 10.1097/BRS.0b013e3181cded6c.
- Jones M, Alshameeri Z, Uhiara O, Rehusek P, Grainger M, Hughes S, et al. En Bloc Resection of Tumors of the Lumbar Spine: A Systematic Review of Outcomes and Complications. *Int J Spine Surg*. 2021;15(6):1223-1233. doi: 10.14444/8155.